

Stent Graft Change Detection after Endovascular Abdominal Aortic Aneurysm Repair.

Josu Maiora¹, Guillermo García², Arantxa Tapia², Iván Macía³, Jon Haitz Legarreta³, Céline Paloc³, Manuel Graña⁴ and Mariano de Blas⁵,

¹ Electronics and Telecommunications Department, ² Engineering Systems and Automatic Department, Technical University School, University of the Basque Country, Donostia-San Sebastián, Spain
{j.maiora, g.garcia, arantxa.tapia}@ehu.es

³ Biomedical Applications Department, VICOMTech, Donostia-San Sebastián, Spain
{imacia, jhlegarreta, cpaloc}@vicomtech.org

⁴ Computational Intelligence Group, Computer Science Faculty, University of the Basque Country, Donostia-SanSebastián, Spain
manuel.grana@ehu.es

⁵ Interventional Radiology Service, Donostia Hospital, Donostia-SanSebastián, Spain
mariano.deblasbravo@osakidetza.net

Abstract. The use of the endovascular prostheses in Abdominal Aortic Aneurysm (EVAR) has proven to be an effective technique to reduce the pressure and rupture risk of aneurysms. Nevertheless, in a long-term perspective different complications, such as prosthesis displacement or leaks inside the aneurysm sac (endoleaks), could appear, causing a pressure elevation and increasing the danger of rupture consequently. At present Computed Tomography Angiography (CTA) is the most commonly used examination for imaging surveillance of stent graft monitoring. However, endoleak complications cannot always be detected by visual inspection on CTA scans. The purpose of this work was to study the application of image registration techniques to the detection of changes in the stent graft. Previously we segment the lumen using semi-automatic methods.

Keywords: image processing, aneurysm, endovascular, registration.

1. Introduction

Abdominal Aortic Aneurysm (AAA) [1] [2] [3] is a focal dilation in some point of the section of the abdominal aorta. Several treatments exist today; one option is a minimally invasive surgical procedure called Endovascular Aneurysm Repair (EVAR), in which an endovascular prosthesis (endovascular graft) is inserted to

exclude the aneurysm from blood circulation [4].

The EVAR (Fig.1) requires a postoperative follow-up to ensure that stent is stable (no leakage, i.e.: blood flow within the aneurysmatic sac) and that the bag was properly excluded from circulation. A reduction in the size of the aneurysm shows that exclusion has been effective [5] [6], while an expansion and/or the presence of a leakage are indicators that the treatment has not been effective, continuing the risk of blood vessel rupture at the aneurysm location.

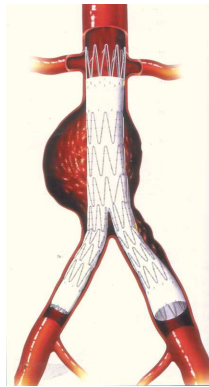


Fig. 1. Endovascular graft

An analysis of the FDA (Food and Drug Administration) estimated that the mortality rate after EVAR is 0.4% annually, compared to 0.18% per annum after open surgery. Therefore, follow-up after EVAR has become an important part of patient care.

The most widely used technique for EVAR monitoring is to obtain Computerized Tomography (CT) images of the abdominal region with intravenous contrast agent. Such images are scans of the patient's abdominal area and they are available in the clinical routine as a set of 2D images that are difficult to interpret and analyze. The aim of our work is to make an automatic analysis of the AAA with visual and quantitative information for monitoring and tracking of patients who underwent EVAR, using digital image processing techniques, which are currently in an advanced state of the art to deal with this problem.

There are several approaches to perform a more accurate EVAR monitoring, one of them is the analysis of the density of the material inside the aneurysmatic sac (thrombus). It detects the various changes experienced in the interior of the aneurysm by analyzing changes in gray levels or image texture. Quantitative assessment of temporal intensity profiles for analysis of trends in EVAR behavior and classification of its states is performed in [8].

The approach that we follow in this paper is to estimate the rigid motion of the stent relative to the spinal cord [9] as well as its deformation [10]. These data can identify patterns for a high probability of dangerous progression of the aneurysm. The long-term goal is to make a prediction about future complications and disease

progression. Because the processes are complex and data from medical devices are difficult to assess visually, a computer-assisted analysis is required. In the current state of the art, the morphological changes and migration of the stent and the aneurysm after EVAR are not studied in a systematic manner to deal with the complexity of these movements.

The segmentation methods used in the state of the art publications are not easily reproducible. Here we use semiautomatic methods that have a proven intrarater and interrater reliability and validity. Segmentation of the spinal canal is based on User Guided Level Set Segmentation method. The same method has been used for the segmentation of the lumen (whose contour is limited by the stent graft, and thus indicates any transformation in it). Aneurysm outer wall or thrombus segmentation has proven to be more difficult. A novel technique for thrombus segmentation, based on region growing algorithms, centerline extraction and radial functions, has been started to be evaluated.

Furthermore, registration methods used by state of the art works are based in point sets registration methods that always suffer a loss of information, therefore in our pipeline, registration is performed over binary images with much less information loss.

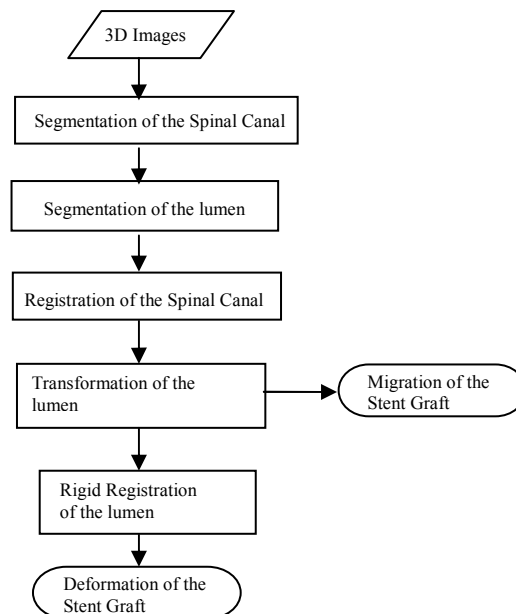


Fig 2.: Pipeline of the process *stent graft change analysis*

We compute the registration of the spinal canal of the last image to the fixation image. This registration allows aligning the two images to the same reference system. After that we compute the rigid registration of the lumen, and therefore, we can

compute and visualize the migration of the stent graft, and at the end of the pipeline we can compute and visualize its elastic deformation.

The work reported in this paper is integrated in a medical image processing platform under development that consists in a module for accessing and managing information. We intend to implement a data base with a user-friendly interface in the hospital information system, through which health professionals have access to all information obtained from the patient's clinical history, from the implantation of EVAR and preoperative and post-operative evaluations (monitoring) of the aneurysm. It allows the introduction, access, and modification of information.

2. Methods

Images obtained by Computerized Tomography (CT) are visualized as 3D volumes with appropriate software tools. We have used ITK based applications (a popular library of image analysis algorithms funded under the Visible Human Project by the U.S. National Library of Medicine) [11] and VTK [12]. First, metaimages were created from computerized tomography slices in DICOM format. This process keeps the resolution and spacing of the original images. The files obtained in this way will be used as inputs for subsequent 3D processing pipeline.

Then, a segmentation process of anatomical structures (spinal canal, lumen) is carried out. We have used a User-Guided Level Set Segmentation (UGLSS) [13] based on the well-known 3D active contour segmentation method called Region Competition [14] to get both the segmented image of the spinal canal and the lumen.

The UGLSS algorithm proceeds as follows: first, the image is resampled into a volume with isotropic spacing (1,1,1). Then, a Region of Interest (ROI) that contains a segmented structure, the spinal canal in the first case, the stent graft (lumen) in the second case, is selected. During the preprocessing, probability maps are computed, by applying a smooth lower and upper threshold. This ensures that voxels inside the spinal canal (and lumen) have a positive value and the outside negative.

We place a seed to initialize the evolving contour into the spinal canal (and lumen) and we establish the parameters that control the propagation velocity and curvature velocity. An evolving contour is a closed surface $C(t,u,v)$ parameterized by variables u, v and by the time variable t . The contour evolves according to the following partial differential equation (PDE):

$$\frac{\partial}{\partial t} C(t,u,v) = F \vec{N},$$

We compute the external force F by estimating the probability that a voxel belongs to the structure of interest and the probability that it belongs to the background at each voxel in the input image:

$$F = \alpha(P_{obj} - P_{bg}) + \beta\kappa$$

Binary images are obtained after segmentation process. Once the structures of interest are segmented, registration is performed. The registration is the process of finding a spatial transform that maps points of an image with its corresponding point in another image. In this case it will be intra-subject and mono-modal, as it examines the same patient on different dates. A sequence of rigid, affine and deformable (B-splines) registrations is performed. The first study is considered the fix image and the others are registered respect to it. A linear interpolator, Mutual Information metric and Regular Step Gradient Descent Optimizer are used.

Rigid, affine and deformable registration of the lumen allows for visual comparison of the evolution of the stent-graft.

As the patient is not exactly placed in the same position in the different studies, the rigid registration of the spinal canal is required to have the same reference system to compare the images. In the registration process we get the transformation parameters that we will use to translate the stent graft of the moving images to the same reference system that we have in the fixed image.

First the two images corresponding to the patient spinal canal are roughly aligned by using a transform initialization and then the two images are registered using a rigid transformation. The parameters of the transformation are then applied to the lumen. When these operations are performed, the migration of the stent graft from one study to the next is visualized.

To compare the deformation of the stent graft, the two stent grafts are registered using the rigid transformation obtained from the spinal canal.

The rigid transformation is used to initialize a registration with an affine transform of the stent graft. The transform resulting from the affine registration is used as the bulk transform of a B-spline deformable transform. The deformable registration is computed, and finally the resulting transform is used to correct the stent graft moving image.

3. Results

We have tested the approach with patients which have been treated with stent-graft devices. The CT image stacks consists of slices with 512 x 512 pixels per slice and a number of 70 to 100 slices, with a thickness of 3 mm and a x-y spacing of 0.684 mm. The time elapsed between different studies varies between 6 and 12 months.

The segmented images are visualized together with a CT slice to have a referenced view (Fig. 3).

After we register the spinal canal, we visualize the migration of the stent graft from one point in time to the next (Fig. 4).

We can compare the stent-graft of two different studies after a rigid registration (Fig. 5). Deformation is visualized.

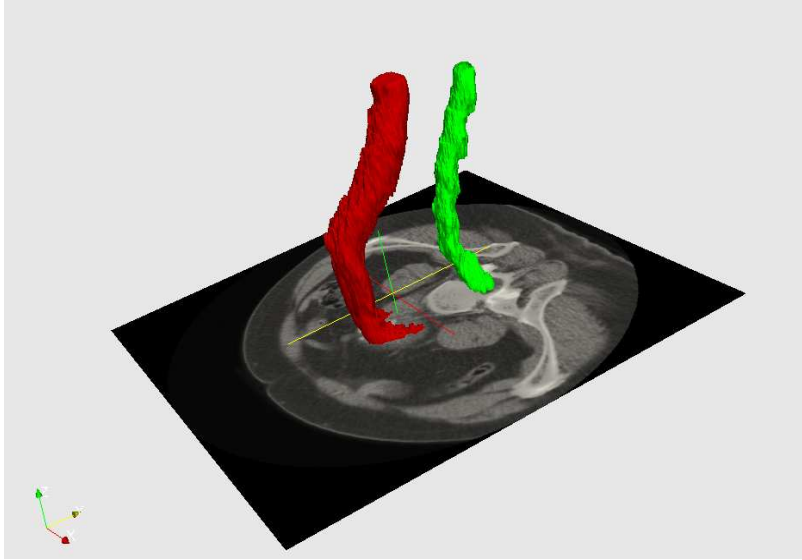


Fig. 3. Segmented spinal canal and lumen with a 3D CT image faded in.

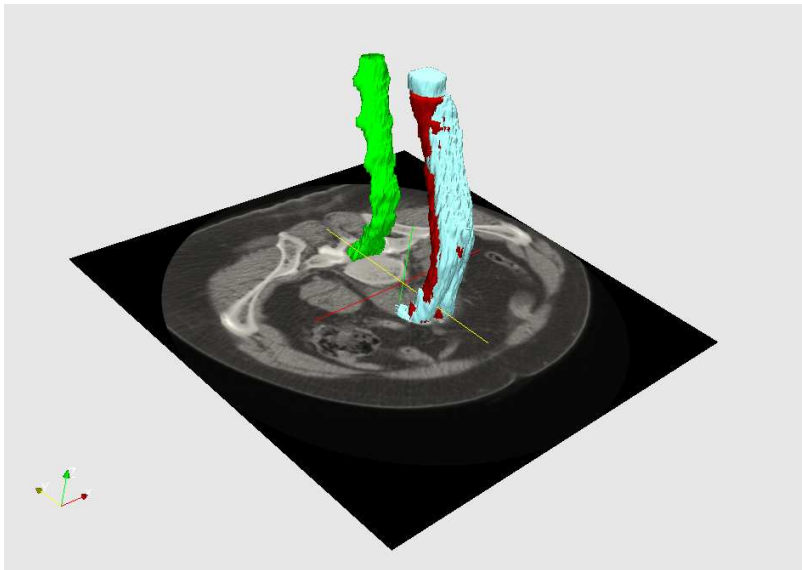


Fig. 4. Stent grafts in different points in time after placing them in the same reference system. Migration is visualized.

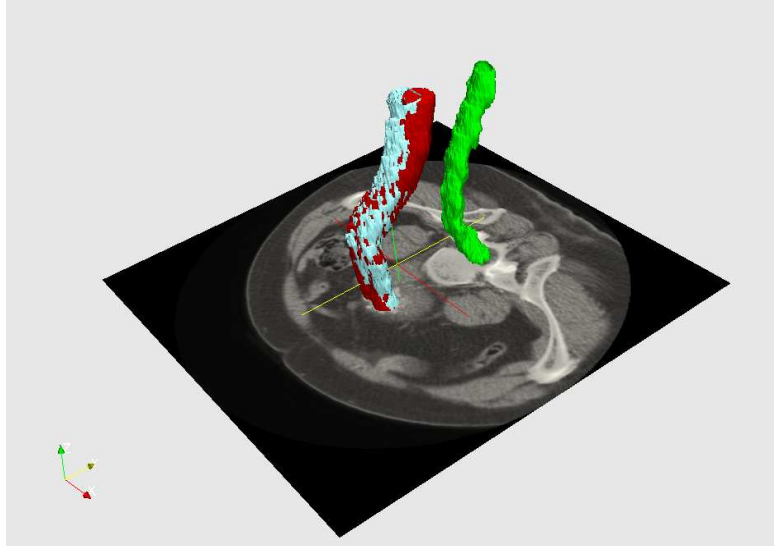


Fig. 5. Stent grafts in different points in time after a rigid registration. Deformation is visualized.

4. Conclusions

We have registered the spinal canal of different studies to place the patient in a single reference system. After segmentation of the lumen in different studies, we have applied them the transformation we get during the spinal canal registration. After this process, migration of the stent graft is visualized. We have observed that vertical movement of the stent occurs.

The registration process is carried out over binary images improving on the works that perform registration over point sets, which always involve a greater loss of information.

To visualize the deformation of the stent graft from one study to the next, a rigid registration is performed. Kinking or buckling phenomenon happen.

As future work, registering images from different studies from a given patient can provide us quantified values of the migration and deformation of the stent graft. The correlation between the values of deformations and the actual evolution of the patient will be stated with the medical team. This could lead to a model that would predict the evolution of other patients and provide support for the decision. Support Vector Machines (SVM) will be used to determine if the evolution of the EVAR is favorable or unfavorable.

This will be part of a more complex database where multiple information about the patients and monitored aneurysm will be available.

Acknowledgments. This work is sponsored and partially financed by the Basque Government through the INTEK Program. We also thank the companies Bilbomatica and eMedica for their participation in this work.

References

1. J.Cronenwett, W.Krupski, R.Rutherford.: Abdominal aortic and iliac aneurysm.Saunders, Philadelphia: Vascular Surgery; p. 1246-80 (2000)
2. Rodin, M. B., Daviglus, M. L., Wong, G. C., Liu, K., Garside, D. B., Greenland, P. And Stamler, J.: Middle Age Cardiovascular Risk Factors Risk Factors and Abdominal Aortic Aneurysms in Older Age. Hypertension, American Heart Association. (2003)
3. U.S. Preventive Services Task Force.: Screening for Abdominal Aortic Aneurysm: Recommendation Statement. Annals of Internal Medicine. Vol 142. No. 3.198-202(2005)
4. J.Parodi, J.Palmaz, and H. Barone.: Transfemoral intraluminal graft implantation for abdominal aortic aneurysms” Ann Vasc Surg. 5(6), pp. 491-499, (1991)
5. Ellozy, S.H., Carroccio, A., Lookestein, R.A., Jakobs T.S., Addis, M.D., Teodorescu, V.J., Marin, M.L.: Abdominal aortic aneurysm sac shrinkage after endovascular aneurysm repair: correlation with chronic sac pressure measurement. J. Vasc. Surg., 43(1): 2-7(2006)
6. Sonesson, B., Dias, N., Malina, M., Olofsson, P., Griffin, D., Lindbland, B., Ivancev, K. : Intra-aneurysm pressure measurements in successfully excluded abdominal aortic aneurysm after endovascular repair. J. Vasc. Surg.; 37(4): 733-8. (2003)
7. Dominik S. Meier, Charles R.G. Guttmann.: Time-series analysis of MRI intensity patterns in multiple sclerosis. NeuroImage 20 1193–1209 (2003)
8. Mattes, J. Steingruber, I. Netzer, M. Fritscher, K. Kopf, H. Jaschke, W. Schubert, R.: Spatio-temporal changes and migration of stent grafts after endovascular aortic aneurysm repair. International Congress Series 1281 393–397(2005)
9. Mattes, J. Steingruber, I. Netzer, M. Fritscher, K. Kopf, H. Jaschke, W. Schubert, R.: Quantification of the migration and deformation of abdominal aortic aneurysm stent grafts [6144-31]. Proc. of SPIE. VOL 6144; PART 1, pages 61440V (2006)
- 10.Ibanez, L., Schroeder, W.: The ITK Software Guide. Kitware, Inc. ISBN 1-930934-10-6, <http://www.itk.org/ItkSoftwareGuide.pdf> (2003)
11. VTK: The visualization toolkit. <http://www.vtk.org>.
12. Paul A. Yushkevich, Joseph Piven, Heather Cody Hazlett, Rachel Gimpel Smith, Sean Ho, James C. Gee, and Guido Gerig.: User-guided 3D active contour segmentation of anatomical structures: Significantly improved efficiency and reliability. *Neuroimage*, Article In Press, (2006)
13. Zhu, S.C., Yuille, A.: Region competition: unifying snakes, region growing, and Bayes/mdl for multiband image segmentation. IEEE Trans. Pattern Anal. Mach. Intell. 18 (9), 884–900 (ISSN 0162-8828) (1996)